



Review Article

Anesthetic management of intestinal obstruction: A postgraduate educational review

S. Parthasarathy, R. Sripriya, N. Krishnaveni

Department of Anaesthesiology and Critical Care, Mahatma Gandhi Medical College and Research Institute, Sri Balaji Vidyapeeth University, Puducherry, India

Corresponding author: Dr. S. Parthasarathy, Department of Anaesthesiology and Critical Care, Mahatma Gandhi Medical College and Research Institute, Sri Balaji Vidyapeeth University, Puducherry - 607 402, India. E-mail: painfreepartha@gmail.com

Abstract

Intestinal obstruction is associated with significant morbidity and mortality. Scientific assessment of the cause, site of obstruction, appropriate correction of the fluid deficit and electrolyte imbalance with preoperative stabilization of blood gases is ideal as a preoperative workup. Placement of a preoperative epidural catheter especially in the thoracic interspace takes care of perioperative pain and stress reduction. Intraoperative management by controlled general anesthesia administering a relative high inspired fraction of oxygen with invasive monitoring in selected sick cases is mandatory. Preoperative monitoring and stabilizing raised intra-abdominal pressure reduces morbidity. Caution should be exercised during opening and closure of abdomen to avoid cardiorespiratory ill effects. There should be an emphasis on avoiding hypothermia. The use of nonsteroidal anti-inflammatory drugs may worsen sick, fragile patients. The use of sugammadex rather than neostigmine will obscure certain controversies in the healing of intestinal anastomotic site. Replacement of blood loss continued correction of fluids and electrolytes with possible postoperative mechanical ventilation in sick cases may improve outcomes in these patients.

Key words: Anesthesia, intestinal obstruction, outcome

INTRODUCTION


Intestinal obstruction accounts for approximately 15–20% of hospitalized patients with an acute abdomen.^[1] The disease is associated with significant morbidity and mortality without proper scientific perioperative care. This review focused on the topic with a holistic approach towards the safer anesthetic outcome.

ETIOLOGY

Intestinal obstruction is classified into (a) dynamic, where the peristalsis is working against a mechanical obstruction and (b) adynamic where there is no peristalsis like paralytic ileus. The fact is that the adynamic obstruction does not present to us (anesthesiologist) so often and hence

This is an open access article distributed under the terms of the Creative Commons Attribution-NonCommercial-ShareAlike 3.0 License, which allows others to remix, tweak, and build upon the work non-commercially, as long as the author is credited and the new creations are licensed under the identical terms.

For reprints contact: reprints@medknow.com

Access this article online		
Website	DOI	Quick Response Code
www.aeronline.org	10.4103/0259-1162.177192	

How to cite this article: Parthasarathy S, Sripriya R, Krishnaveni N. Anesthetic management of intestinal obstruction: A postgraduate educational review. *Anesth Essays Res* 2016;10:397-401.

it is not considered here. Among the dynamic causes, adhesions, and malignant tumors are the commonest cause in developed countries, while obstructed hernia is common in developing countries.^[2-5] Whereas volvulus, intussusceptions, ischemic enteritis, polyps, and masses present as rarer ones. The causes described above are pertinent to adults while worms and intussusceptions are the common causes in pediatric patients.^[6] The classification extends in different faces such as the site upper small bowel, lower small bowel, and large bowel; duration: Acute or chronic, whether there is a mesenteric blood flow compromise or not, i.e. strangulated or not.^[7]

PATHOPHYSIOLOGY

Intestinal obstruction is presented as abdominal distension due to sequestration of fluid and gas within the lumen. Of this, accumulation of fluid accounts for most of the bowel distension. As intraluminal pressure increases, the secretory function of the bowel increases progressively probably mediated by prostaglandin. In addition, reabsorption is impaired once intraluminal pressure exceeds 20 cm H₂O. The next component intestinal gas is a mainly result from swallowed air. Continuous bowel distension from the ongoing gas and fluid accumulation lead to a rise in intraluminal and intramural pressures. The gaseous distension may partially be due to bacterial overgrowth. Once the edematous bowel gives way, it leads to peritonitis and concurrent sepsis. The classy difference is that even the giving way of the mucosal barrier may lead to bacteremia and sepsis even in the absence of frank perforation and leak. The increased intramural pressures can also lead to progressive interference with the mesenteric blood supply, resulting in a strangulated obstruction (gangrene) and perforated bowel with increasing morbidity and mortality. If gangrene ensues, the mortality rate may go up to 20–40% from 10% in intestinal obstructions. In small bowel obstruction, the abdominal distension exerts pressure on the diaphragm, limiting its downward movement, resulting in inadequate ventilation and an increased work of breathing in a patient who may already be malnourished. It is especially significant if the stomach is also distended. The decrease in tidal volume and the reduction in functional residual capacity result in a low PaO₂ and an elevated PaCO₂. Upper small bowel obstruction leads to hydrogen, chloride and potassium loss leading to hypovolemic, hypochloremic, and hypokalemic metabolic alkalosis. Instead, if the obstruction is relatively distal, the intestinal juice contains more bicarbonate than chloride. The inflamed bowel can lead to loss of protein. Hence, acidosis and hypoalbuminemia and its consequent fluid shifts can complicate management. In large bowel obstruction, accumulation of methane may result in hyperammonemia and alkalosis.^[8] These acid-base changes may end up in acidosis if septic shock ensues. In large bowel obstruction, except volvulus, the fluids shifts are slow and insidious.

PREANESTHETIC CHECKUP

The four cardinal signs and symptoms of intestinal obstruction are a crampy abdominal pain, vomiting, obstipation, and abdominal distension. Three major systems, fluid and electrolyte status, hemodynamics and intra-abdominal hypertension (IAH) should be optimized preoperatively.

Fluid and electrolyte status

The presentation may vary from mild dehydration to septic shock. In the fluid loss, what is special is the hidden intraluminal accumulation of fluid and the difficulty in its assessment. There may be a loss of red blood cells (RBCs) also in the gangrene gut which leads to severe anemia. In case, there is no RBC loss, if the hematocrit has risen to 55%, approximately 40% of plasma and extracellular fluid volume has been lost.

The 24 h normal secretion of the gastrointestinal tract in ml is - saliva 1000 ml, stomach 2000 ml, pancreas 2000 ml, bile 1000 ml, succus entericus 1000 ml.^[9] Preoperative correction of electrolyte disturbances and dehydration to get an adequate urine output for at least 4 h prior to surgery decreases mortality in such cases. The fluid correction done based on the degree of obstruction - mild: 1500 ml, moderate: 3000 ml, and severe with shock: 6–8 L [Table 1].

It has to be emphasized that these are rough guidelines and decision to infuse has to be made on individual cases. Ringer lactate is close to plasma, and it is the fluid of choice in most cases. Yet if the vomiting is significant with associated hyponatremia, normal saline can be supplemented.

Hemodynamics

The assessment of stable pulse rate, good volume, improvement of blood pressure, urine output of more than 0.5 ml/kg/h are favorable signs of rehydration. Inotropes and elective ventilation should be considered in patients with acidosis and shock. Monitoring and idealizing central venous pressure is a must in most of the cases.

Intra-abdominal hypertension

Plain abdominal radiographs show presence of multiple air-fluid levels in small bowel obstruction^[10] [Figure 1]. Ryles tube aspiration can decompress the stomach.^[11] Levin, sump and Miller–Abbott tubes^[12,13] have been described to achieve intestinal decompression. A tense abdominal wall can promote reverse peristalsis, decrease venous

Table 1: Hourly maintenance fluid requirements

Weight (kg)	Volume in ml
<10	4 ml/kg
10-20	40 ml + 2 ml/kg for every kg >10
>20	60 ml + 1 ml/kg for every kg >20 kg

return and increase anesthetic and relaxant requirement. We should be aware about IAH and its consequence on hepatic blood flow and drug dose adjustments. There is a compromise in the renal blood flow in patients with IAH and a few selected cases adequate rehydration may not yield a satisfactory preoperative urine output. The central venous pressure may not guide fluid therapy in a few cases in IAH.^[14,15] It should be remembered in most of the cases that intervention with rehydration, stabilizing renal, and blood gas parameters is an emergency, but the surgical procedure can be postponed after achieving the above. Because of impaired bowel function, Vitamin K supplements preoperatively can be considered in selected cases.

Investigations

All the routine blood and urine investigations including a liver and renal function tests, blood gases, an electrocardiogram (ECG) which may show prior diseases or electrolyte abnormalities, an X-ray chest suggesting atelectasis should be ordered. A possible diagnosis should be arrived at with investigations including ultrasonogram, computed tomography abdomen, magnetic resonance imaging abdomen, etc., in specific cases.^[16,17]

We should always remember that a simple assessment of tongue, urine, pulse volume, respiratory rate, blood pressure, SaO₂ can separate sick from the ordinary. Needless to say, the strict adherence to a preanesthetic protocol which includes assessment of airway, spine, and optimizing any other systemic illness gets no less a priority.

INTRAOPERATIVE MANAGEMENT

Anesthetic plan

Controlled general anesthesia (GA) with or without continuous epidural anesthesia is the choice among the

techniques used.^[18-21] If the coagulation profile remains normal, the possibility of additional regional technique, for example, an insertion of the epidural catheter in the thoracic interspace will solve most of the problems of perioperative pain and stress. Hence, in many of the cases, a shot of 6–8 ml of 0.25% bupivacaine with fentanyl or morphine in the thoracic epidural catheter before induction with continued doses in the postoperative period is acceptable. Regional anesthesia alone has been successfully used in patients with pulmonary compromise.^[22,23]

Premedication

The premedication in these patients is perplexing. If the stomach is full, the use of H₂ antagonists and metoclopramide may not be that useful as like other cases. Yet, these may be considered. Anticholinergics have a limited role because of associated tachycardia. An adequate dose of narcotic, for example, morphine (0.1 mg/kg) or fentanyl (2 µg/kg) with midazolam intravenous (IV) before induction is optimal.

Intraoperative anesthetic management

A rapid sequence induction (RSI) with a minimal dose of thiopentone and adequate succinylcholine with cricoid pressure is used by many. Any untoward event during RSI may lead to aspiration and concomitant lung damage [Figure 2]. Etomidate as induction agent can be useful in hemodynamically unstable patients. Air, O₂, the agent is better than using nitrous oxide because of its propensity of the latter to increase closed air spaces and complicate distension.^[24,25] More commonly, it will cause difficulties with abdominal closure at the conclusion of surgery. A drastic hypotension after abdominal opening may ensue in patients where IAH has contributed significantly to mesenteric vascular compromise. Administration of a high concentration of inspired oxygen

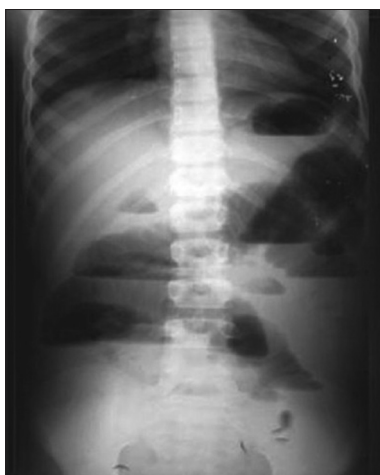

Figure 1: Plain X-ray abdomen erect posterior-anterior view shows multiple air-fluid levels with features of small bowel obstruction. No free air under the diaphragm. Fat plane psoas shadow are normal

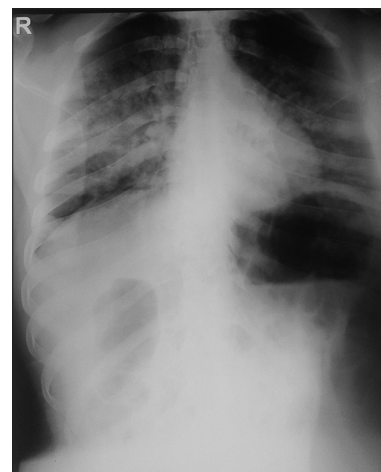


Figure 2: Bedside supine X-ray chest anterior-posterior view shows multiple inhomogeneous airspace opacities in the right lung mid zone and both side lower zones - likely aspiration pneumonitis. Cardiac silhouette, pleural spaces, and soft tissues are normal

may lead to a reduction in the incidence of surgical wound infections and hence we prefer to use 40–50% oxygen. In a study, it was shown that the incidence of postoperative colonic dysfunction is slightly higher in propofol-based techniques than inhalational agent-based techniques.

Monitoring

Monitoring of pulse, blood pressure, central venous pressure, ECG, EtCO₂, urine output is routine yet it is mandatory to monitor and maintain temperature, surgical field, and blood loss. In some sick patients, arterial blood gas monitoring during the procedure may be helpful. Blood and IV-fluid warmers are used to avoid perioperative hypothermia. Special reservations are necessary for extremes of age.

Pediatrics

In infants with obstruction, fluid management is as 4:2:1 rule [Table 1]. An additional allowance of 6–10 ml/kg/h should be added to compensate for evaporation from an open wound, and further boluses may be required depending on the extent of bowel trauma and accompanying sepsis. Techniques in monitoring and administration of controlled GA are similar to adults. All other specialized procedures for infants are beyond the scope of this discussion.

Extubation

To and not to reverse these patients with neostigmine is mauld with controversies. Neostigmine by virtue of its effects on gut can cause disruption of anastomotic site.^[26-28] Yet many anesthesiologists continue to reverse with neostigmine without much problems. The use of rocuronium and sugammadex in reversal may answer some questions raised on this regard.

POSTOPERATIVE CARE

Many of the cases may require elective postoperative ventilation which will be decided on individual basis with an eye on preoperative hemodynamics, intraoperative behavior and extent of surgical trauma. It should be emphasized that suturing after removal of a dead gut does not solve the problems the patients encounter. The continued monitoring of cardiorespiratory parameters, the use of inotropes, mechanical ventilation, optimizing blood gas values, fluid and electrolyte status remains the mainstay in the recovery of patients. Hence, the use of selected antibiotics, thromboembolism prophylaxis, and commencement of early enteral nutrition with an eye on abdominal distension is significant. Monitoring intra-abdominal pressure (IAP) with the Foley's catheter and continuance of strict vigilance on other parameters till the IAP comes down below 20 is essential. Continued care of postoperative pain preferably by low dose local anesthetic-fentanyl epidural administration is suited to prevent atelectasis and pneumonia. Use of nonsteroidal

anti-inflammatory drugs is to be cautious in frail, elderly, dehydrated salt-depleted patients.^[29]

CONCLUSION

A proper preoperative assessment with correction of fluid, electrolyte, acid-base, hemodynamic, and respiratory imbalance prior to surgery is a must. Continuous epidural with controlled GA is the best option. Intraoperative maintenance of all the parameters with a special reference to the usually neglected temperature monitoring is the key to the successful outcome. Persistent postoperative care toward the basics with an eye on abdominal compartment syndrome is certain to improve outcomes in sick obstructions.

Financial support and sponsorship

Nil.

Conflicts of interest

There are no conflicts of interest.

REFERENCES

1. Brunicaudi FC, editor. Schwartz's Principles of Surgery. 8th ed. New York: McGraw-Hill; 2005. p. 1017-32.
2. Deutsch AA, Eviatar E, Gutman H, Reiss R. Small bowel obstruction: A review of 264 cases and suggestions for management. *Postgrad Med J* 1989;65:463-7.
3. Bevan PG. Acute intestinal obstruction in the adult. *Br J Hosp Med* 1982;28:258, 260-5.
4. Lee SH, Ong ET. Changing pattern of intestinal obstruction in Malaysia: A review of 100 consecutive cases. *Br J Surg* 1991;78:181-2.
5. Chiedozi LC, Aboh IO, Piserchia NE. Mechanical bowel obstruction. Review of 316 cases in Benin City. *Am J Surg* 1980;139:389-93.
6. Ramamurthi RJ. Anaesthesia for intestinal obstruction in children, anaesthesia. UK: Anaesthesia Tutorial of the Week; 2007.
7. Botteril ID, Sagar PM. Intestinal obstruction. *Surgery* 1998;16:221-7.
8. Gemmell LW, Rincon C. Anesthetic management of intestinal obstruction. *Br J Anaesth* 2005;1:138-41.
9. Phillips SF. Diarrhea: A current view of the pathophysiology. *Gastroenterology* 1972;63:495-518.
10. Silva AC, Pimenta M, Guimarães LS. Small bowel obstruction: What to look for. *Radiographics* 2009;29:423-39.
11. Holdsworth JD, Furness RM, Roulston RG. A comparison of apomorphine and stomach tubes for emptying the stomach before general anaesthesia in obstetrics. *Br J Anaesth* 1974;46:526-9.
12. Wyndham NR. The Miller-Abbott tube in the treatment of ileus. *Aust N Z J Surg* 1946;16:62-7.
13. Loe RH, Tuohy CE Jr. Technic and indications for Miller-Abbott tube intubation; a rapid method of introduction. *Am J Surg* 1959;98:160-4.
14. Hunter JD, Damani Z. Intra-abdominal hypertension and the abdominal compartment syndrome. *Anaesthesia* 2004;59:899-907.
15. Moore AF, Hargest R, Martin M, Delicata RJ. Intra-abdominal hypertension and the abdominal compartment syndrome. *Br J Surg* 2004;91:1102-10.
16. Silva AC, Pimenta M, Guimarães LS. Small bowel obstruction: What to look for. *Radiographics* 2009;29:423-39.
17. Maglinte DD, Heitkamp DE, Howard TJ, Kelvin FM, Lappas JC. Current concepts in imaging of small bowel obstruction. *Radiol Clin North Am* 2003;41:263-83, vi.
18. Gould TH, Grace K, Thorne G, Thomas M. Effect of thoracic epidural anaesthesia on colonic blood flow. *Br J Anaesth* 2002;89:446-51.
19. Patel S, Lutz JM, Panchagnula U, Bansal S. Anesthesia and perioperative management of colorectal surgical patients – A clinical review (Part 1). *J Anaesthesiol Clin Pharmacol* 2012;28:162-71.
20. Scott AM, Starling JR, Ruscher AE, DeLessio ST, Harms BA. Thoracic versus lumbar epidural anesthesia's effect on pain control and ileus resolution after restorative proctocolectomy. *Surgery* 1996;120:688-95.

21. Rigg JR, Jamrozik K, Myles PS, Silbert BS, Peyton PJ, Parsons RW, et al. Epidural anaesthesia and analgesia and outcome of major surgery: A randomised trial. *Lancet* 2002;359:1276-82.
22. Aitkenhead AR, Wishart HY, Brown DA. High spinal nerve block for large bowel anastomosis. A retrospective study. *Br J Anaesth* 1978;50:177-83.
23. Savas JF, Litwack R, Davis K, Miller TA. Regional anesthesia as an alternative to general anesthesia for abdominal surgery in patients with severe pulmonary impairment. *Am J Surg* 2004;188:603-5.
24. Myles PS, Leslie K, Chan MT, Forbes A, Paech MJ, Peyton P, et al. Avoidance of nitrous oxide for patients undergoing major surgery: A randomized controlled trial. *Anesthesiology* 2007;107:221-31.
25. Eger EI 2nd, Saidman LJ. Hazards of nitrous oxide anesthesia in bowel obstruction and pneumothorax. *Anesthesiology* 1965;26:61-6.
26. Bell CM, Lewis CB. Effect of neostigmine on integrity of ileorectal anastomoses. *Br Med J* 1968;3:587-8.
27. Child CS. Prevention of neostigmine-induced colonic activity. A comparison of atropine and glycopyrronium. *Anaesthesia* 1984;39:1083-5.
28. Wilkins JL, Hardcastle JD, Mann CV, Kaufman L. Effects of neostigmine and atropine on motor activity of ileum, colon, and rectum of anaesthetized subjects. *Br Med J* 1970;1:793-4.
29. Thompson JS, Baxter BT, Allison JG, Johnson FE, Lee KK, Park WY. Temporal patterns of postoperative complications. *Arch Surg* 2003;138:596-602.

