



## USE OF ELECTRO ACUPUNCTURE IN THE TREATMENT OF COMPLEX REGIONAL PAIN SYNDROME – A CASE SERIES STUDY

<sup>1</sup>Dr. S. Parthasarathy MD DA DNB PhD FICA, <sup>2</sup>Dr. M. Thirilogasundry MD.

<sup>1</sup>Associate Professor, Department of Anaesthesiology and Critical Care, Mahatma Gandhi Medical College and Research Institute, Sri Balaji Vidyapeeth University, Pillayarkuppam, Puducherry – 607402. India.

<sup>2</sup>Assistant Professor, Department of Anaesthesiology and Critical Care, Mahatma Gandhi Medical College And Research Institute, Sri Balaji Vidyapeeth University, Pillayarkuppam, Puducherry – 607402. India.

**\*Author for Correspondence: Dr. S. Parthasarathy MD DA DNB PhD FICA**

Associate Professor, Department of Anaesthesiology and Critical Care, Mahatma Gandhi Medical College and Research Institute, Sri Balaji Vidyapeeth University, Pillayarkuppam, Puducherry – 607402. India.

Article Received on 30/09/2015

Article Revised on 24/10/2015

Article Accepted on 18/11/2015

### ABSTRACT

Complex regional pain syndrome (CRPS) is a common chronic pain entity resulting from an exaggerated sympathetic response of limbs exposed to injury. The aetiology of CRPS is poorly understood. The salient clinical features include pain and muscle dystrophy progressing to atrophy. Electro acupuncture is a unique treatment modality which administers pulsating electric current through the acupuncture needle tips. The possible actions of electro acupuncture may be analgesia with muscle stimulation which directly targets the pathology of CRPS. Hence we decided to try electro acupuncture for CRPS and report a series of 10 cases for which electro acupuncture was successfully used. The pain relief and reduction of oedema was significant in all the cases.

**KEYWORDS:** chronic pain, complex regional pain syndrome, acupuncture, electrical stimulation.

### INTRODUCTION

Complex regional pain syndrome (CRPS), earlier called by several names such as causalgia, Sudeck's atrophy, shoulder hand syndrome, algo dystrophy, algo neurodystrophy, reflex neurovascular dystrophy, post-traumatic dystrophy and reflex sympathetic dystrophy is characterised by an increased response of a limb to injury, clinically manifested by intense prolonged pain, vasomotor disturbances, delayed functional recovery with trophic changes. The distribution of clinical signs in individual patients varies considerably; the main problems being pain, muscle atrophy and stiffness. In the current clinical scenario, the treatment of CRPS is not very well defined.

The management includes analgesics, interferential therapy, physiotherapy, hot fomentation, intravenous sympatholytic drugs, sympathetic nerve blocks and so on.<sup>[1]</sup> There are effects and side effects with all these modalities. The main actions of electro acupuncture are pain relief and stimulation of flaccid muscles with pulsatile electric current. As these actions of acupuncture suited with the basic problems in CRPS i.e. pain and motor stiffness, we used this technique for the successful management of CRPS.

### Case reports and methodology

Continuous ten adult patients of either sex diagnosed with complex regional pain syndrome of either upper or lower

limbs were chosen for our study. Patients with a known history of trauma having features of pain in the affected limbs, warmth, oedema, weakness of muscles with variable atrophic changes were selected for the intervention. All patients satisfied the Budapest criteria for CRPS.<sup>[2]</sup> In all the ten patients the symptomatology was between 3 – 5 months. The distribution and severity of clinical signs varied between individual patients.

All the patients belonged to type I CRPS and had no evidence of neurological injury. Systemic investigations were done to rule out metabolic diseases and were within normal limits. All patients had nociceptive pain without any evidence of arthritis. The distal peripheral vasculature was normal. There was no fever in any of the cases. None of the patients had contraindications of electro acupuncture like seizures. Patients were educated about visual analogue score prior to initiation of treatment.

All patients were planned to start electro acupuncture at specified points. Du20, Hegu, Sp6, Dechi<sup>[3]</sup> were the commonly used points. The points differed with limb affected. Specific acupuncture points were also chosen on the affected and contra lateral limb. The insertion of needles was done by an expert who has used needling for more than thousands of patients over two decades. Electrical stimulation was done with dense disperse type and a frequency of 100-150 Hz was used to stimulate accepted points for twenty to thirty minutes. The output of

the machine was standardized prior. A minimal tingling sensation felt at the site of stimulation was the target which was achieved in all cases. Any reduction in VAS of more than 2 was considered significant. We measured the difference in circumference between the affected and unaffected limb at the level of wrist or ankle joint; once before start of treatment and then two weeks after treatment. We then calculated the percentage of reduction of oedema based on the difference between the two metric values. Any reduction of more than 25 % was taken as significant. Any injury, bleeding and adverse events were monitored and noted. A long term follow up for three months with an advice to continue minimal household physiotherapy was done to substantiate our findings. An achievement of full range of painless movement of the fingers was taken as complete motor recovery.

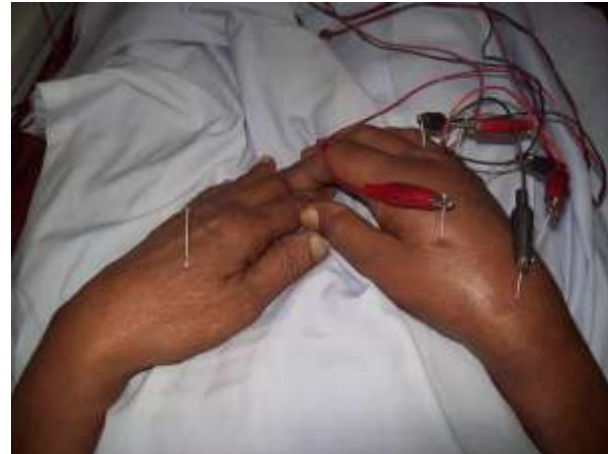

Fig 1 showing acupuncture needles in situ

**RESULTS**

The mean age of our patients was 54.6 ± 7.4 years. The male: female ratio was 8:2. All our patients successfully completed the intervention without any side effects. There were five each in upper and lower limbs respectively. All patients had significant reduction in pain scores by day 1, which improved dramatically over the next 8 – 9 days. (Table.1) There was gross reduction in limb oedema and the appearance returned to almost a normal looking limb two weeks after the treatment in all the ten cases. (figure 1). Patients were advised to continue minimal physiotherapy. Stiffness of muscles reduced to a great extent with significant improvement to attain complete motor power after two months. All patients were followed up for three months and had normal sensory and motor functions.

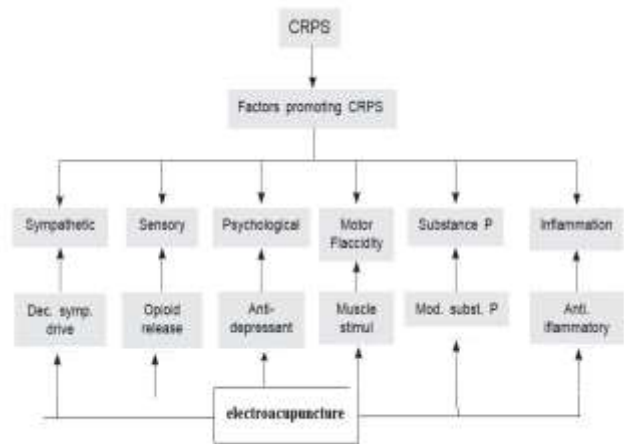


Fig 2 showing Multimodal pathophysiology of CRPS and similar multimodal possible treatment effects of electroacupuncture

Table No.:1

s.no.	Age	sex	Diagnosis	Site	Pre treatment VAS	Post treatment VAS	Oedema reduction
1	55	M	CRPS	Wrist	8	2	75%
2	45	M	CRPS	Ankle	9	3	50%
3	61	M	CRPS	Wrist	8	2	50%
4	47	F	CRPS	Wrist	10	4	25%
5	57	M	CRPS	Ankle	7	2	75%
6	52	M	CRPS	Ankle	8	2	75%
7	48	M	CRPS	Ankle	8	2	75%
8	68	F	CRPS	Ankle	9	1	100%
9	58	M	CRPS	Wrist	10	3	75%
10	55	M	CRPS	Wrist	8	1	75%

**DISCUSSION**

Conventional treatment for CRPS includes NSAIDs, tricyclic antidepressants and opioids along with physiotherapy. Long term use of oral analgesics leads to several systemic complications. Various interventional treatment modalities have also been described for CRPS treatment such as stellate ganglion block, brachial plexus blocks, epidural/ spinal infusions, lumbar sympathectomy,

intravenous regional anaesthesia etc. All these procedures are more invasive than acupuncture and may be associated with several complications – nerve injury, motor weakness, hypotension, bleeding, infection to name a few. Many a time, these may be in-hospital procedures which complicate the compliance.<sup>[4]</sup>

Electro acupuncture was effective in treating CRPS in all the patients and was devoid of major side effects in expert hands. Benefits of electro acupuncture are multimodal – the acupuncture needle stimulates release of endogenous opioids, anti-inflammatory mediators but decreases substance P production at nerve endings. It activates release of corticotrophin releasing hormone at hypothalamus.<sup>[5]</sup> The electrodes stimulate contraction of individual muscle fascicles, thus improve muscle atrophy and reduce oedema. (Fig.2) We had excellent analgesia with the use of electro acupuncture in our case series. Similar results were obtained in case series done by Chan and Chow<sup>[6]</sup> and Liu *et al.*<sup>[7]</sup> They claimed that response to electro acupuncture was equivalent to that obtained by interferential therapy. Addition of pulsating electrode current to the acupuncture needles obviated the need for manual manipulation of needles by the physician. In our series we had not used goniometric studies to assess improvement, but it was only subjective and clinical. Hommer *et al* successfully used scalp acupuncture for CRPS with effective analgesia.<sup>[8]</sup> We have used conventional acupuncture instead of scalp acupuncture with similar results. The limitation of our study is that we have not compared either with other modes of treatment or sham acupuncture. Still our results prompt us to take up this intervention in large sample size to establish the efficacy of acupuncture on CRPS.

## CONCLUSION

We conclude that electro acupuncture is a very effective treatment for complex regional pain syndrome. It produces remarkable functional outcome of the affected limb with Establishment of effective early analgesia, with no significant untoward side effects.

## REFERENCES

1. Lynne Turner-Stokes and Andreas Goebel. Complex regional pain syndrome in adults: concise guidance. *Clinical Medicine.*, 2011; (11)6: 596–600.
2. Harden RN, Bruhl S, Perez RSGM, *et al.* Validation of proposed diagnostic criteria (the “Budapest criteria”) for complex regional pain syndrome. *Pain.*, 2010; 150: 268–74.
3. Cho TH, Park KMJ. Complex regional pain syndrome type 1 relieved by acupuncture point injections with placental extract. *Acupunct Meridian Stud.*, 2014; 7(3): 155-8.
4. C. L. Jeng, T. M. Torrillo and M. A. Rosenblatt. Complications of peripheral nerve blocks. *British Journal of Anaesthesia*, 2010; 105: i99-107.
5. Kwokming James. Cheng. Neurobiological Mechanisms of Acupuncture for Some Common Illnesses: A Clinician's Perspective. *Journal of Acupuncture and Meridian Studies.*, 2014; (7)3: 105–11.
6. Chan CS, Chow SP. Electroacupuncture in the treatment of post-traumatic sympathetic dystrophy (Sudeck's atrophy). *Br J Anaesth* 1981; 53(8): 899-902.
7. Liu H, Zhang C. 60 cases of shoulder-arm syndrome treated by electro-acupuncture at bingfeng(SI 12). *J Trad Chin Med.*, 1998; 18(4): 256-8.
8. Hommer DH. Chinese scalp acupuncture relieves pain and restores function in complex regional pain syndrome. *Mil Med.*, 2012; 177(10): 1231-4.